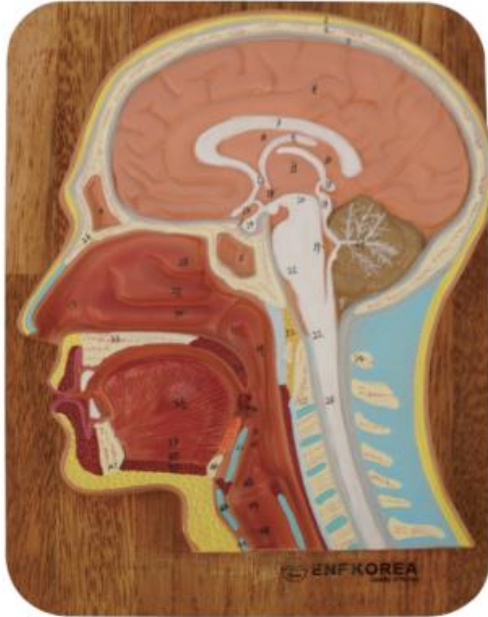


EC41 (HEAD SECTION MODEL)



1. Head
2. Skull
3. Superior sagittal sinus
4. Frontal sinus
5. Sphenoidal sinus

6. Cerebrum
7. Corpus callosum
8. Septum pellucidum
9. Fornix
10. Choroid plexus of third ventricle
11. Interthalamic adhesion
12. Anterior commissure
13. Optic chiasm
14. Hypophysis
15. Pineal body
16. Posterior commissure
17. Cerebellum
18. 3rd Ventricle
19. 4th Ventricle
20. Mid brain tegmentem
21. Pons
22. Medulla oblongata
23. Spinal cord
24. Atlas
25. Axis
26. Bony septum of nose
27. Nasal cavity
28. Superior nasal concha
29. Middle nasal concha
30. Inferior nasal concha
31. Opening of pharyngotympanic (auditory) tube
32. Pharyngeal tonsil
33. Hard palate
34. Soft palate
35. Palatine tonsil
36. Tongue
37. Genioglossus muscle
38. Geniohyoid muscle
39. Mylohyoid muscle
40. Hyoid bone
41. Mandible
42. Epiglottis
43. Thyroid cartilage
44. Cricoid cartilage
45. Vestibule
46. Vestibular folds
47. Vocal fold
48. Infraglottic cavity
49. Nasopharynx
50. Oropharynx
51. Laryngopharynx